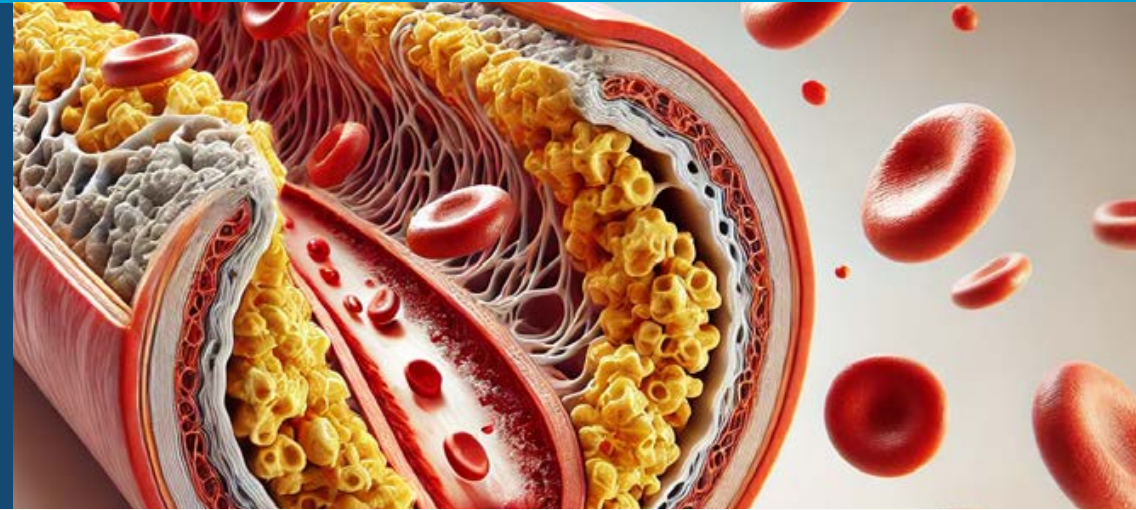


Case report RePair

K.W., 56 years old, female, type 1 diabetes mellitus for more than 40 years with diabetic foot syndrome with complete occlusion of the fibular artery and a non-healing foot ulcer on the left leg. The indication for an amputation of the lower ankle joint had already been established.



Individual healing trial with RePair over a period of three weeks.

Result:

Immediate improvement in general condition, ulcer healed completely within 8 weeks.

Angiogram after 6 months:

Reopening of the occluded vessel and additional collateral blood flow into the left foot.

(Pfützner A et al., Diabetes Stoffw. Herz 32 (2023) 241-244)



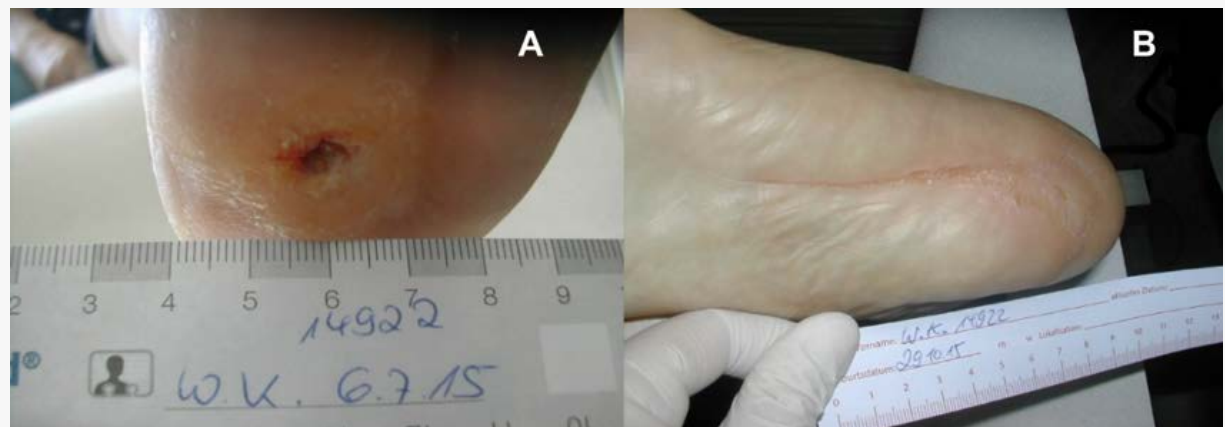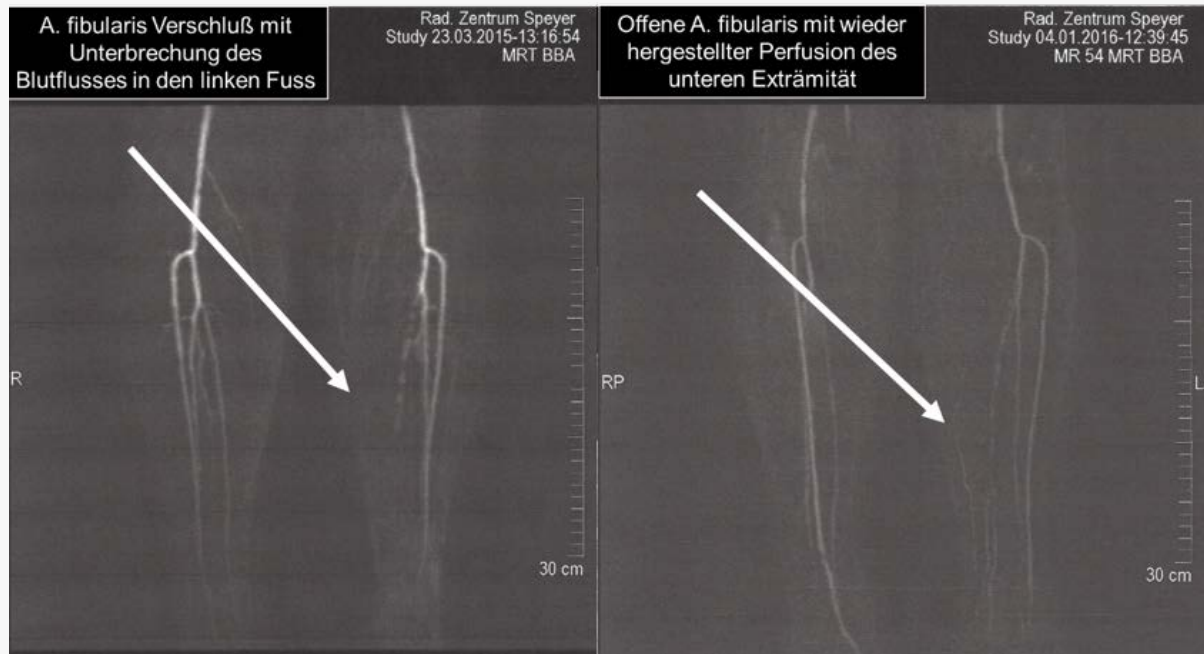Personalized and
innovative diabetes treatments

Private practice Prof. Dr. Dr. Andreas Pfützner
Haifa-Allee 18
55128 Mainz

Tel. +49 6131 5884640
Fax +49 6131 5884644

info@pfuetzner-mainz.com
www.pfuetzner-mainz.com

Case report RePair



Personalized and
innovative diabetes treatments

Private practice Prof. Dr. Dr. Andreas Pfützner
Haifa-Allee 18
55128 Mainz

Tel. +49 6131 5884640
Fax +49 6131 5884644

info@pfuetzner-mainz.com
www.pfuetzner-mainz.com